

When and Why to Refer

Common Questions

- “When is the best time for my child to get braces?”
- “If we start too early won’t the teeth be more likely to move back?”
- “We thought we shouldn’t see an orthodontist because my child still has baby teeth.”



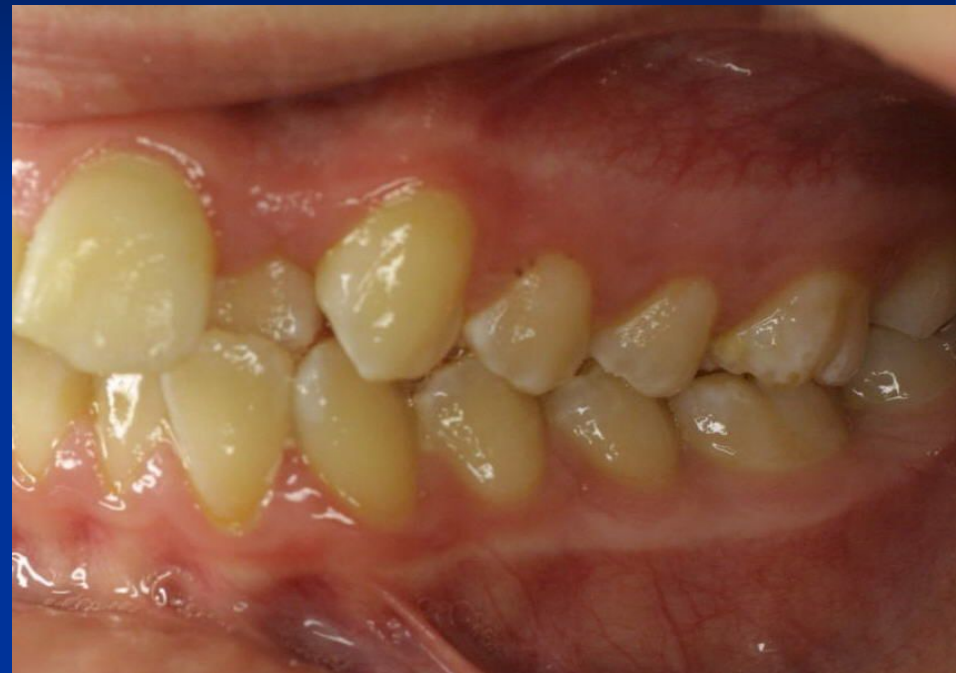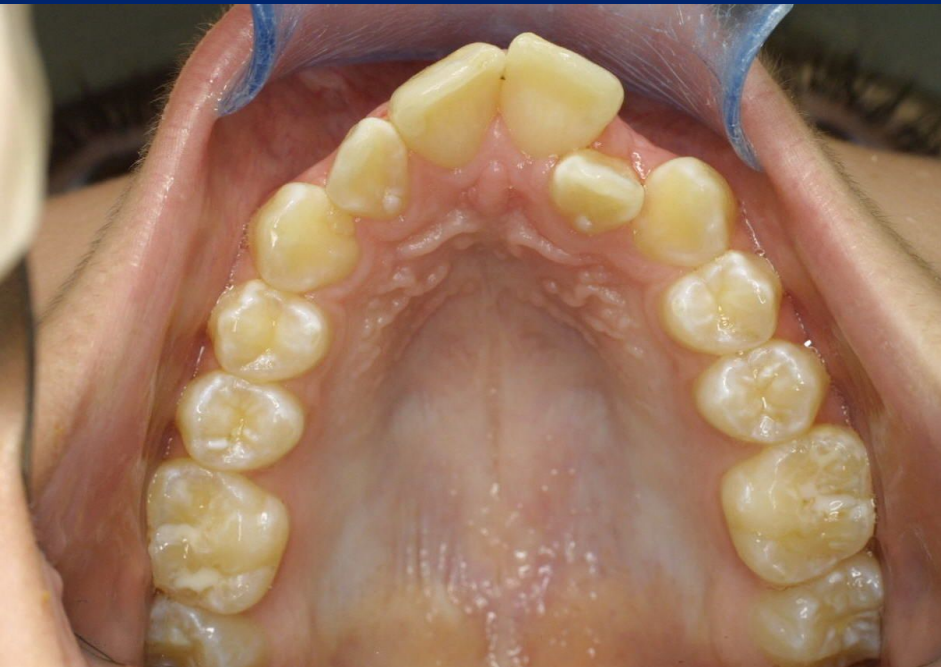Indications of Treatment

- Crossbites
- Soft tissue considerations
- Functional shift
- Skeletal class II or class III
- Crowding
- Poor esthetics
- Ectopic teeth
- Missing teeth
- SN teeth

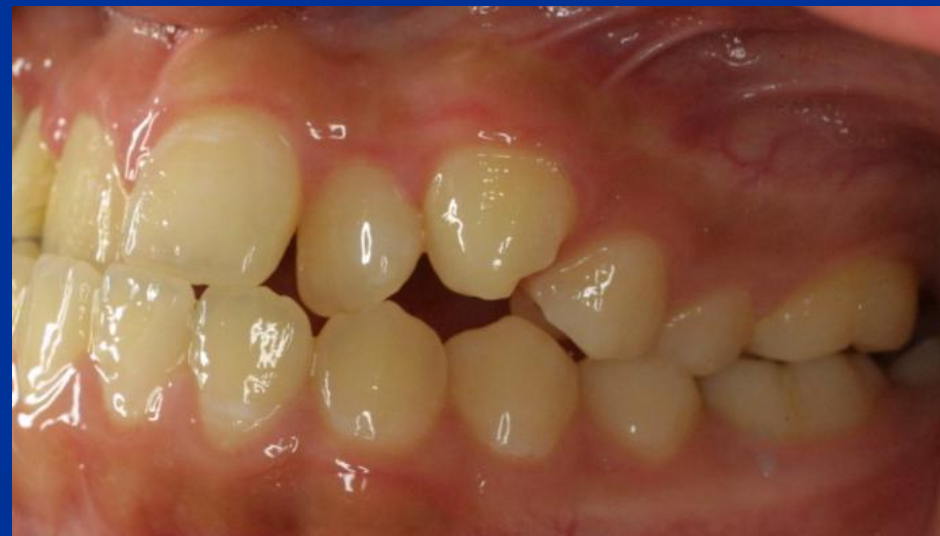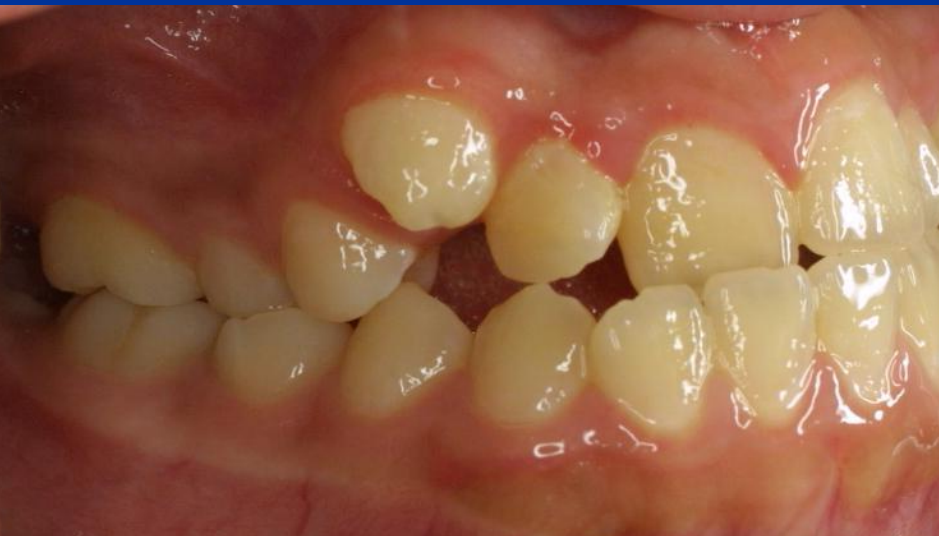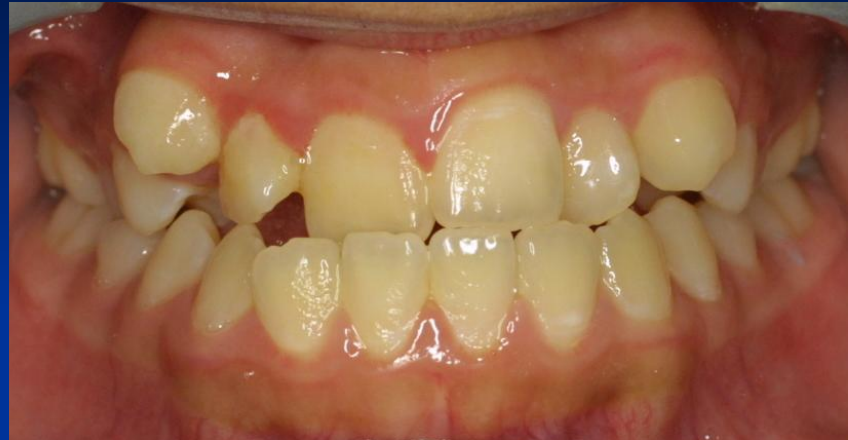4 Types of Crossbites

- Skeletal: Crossbite resulting from the malposition of the maxilla, mandible or both
- Dental: Crossbite resulting from the malposition of the teeth
- Combination
- Functional: Crossbite resulting from a mandibular shift into an abnormal position (e.g. “Pseudo - Class III”)

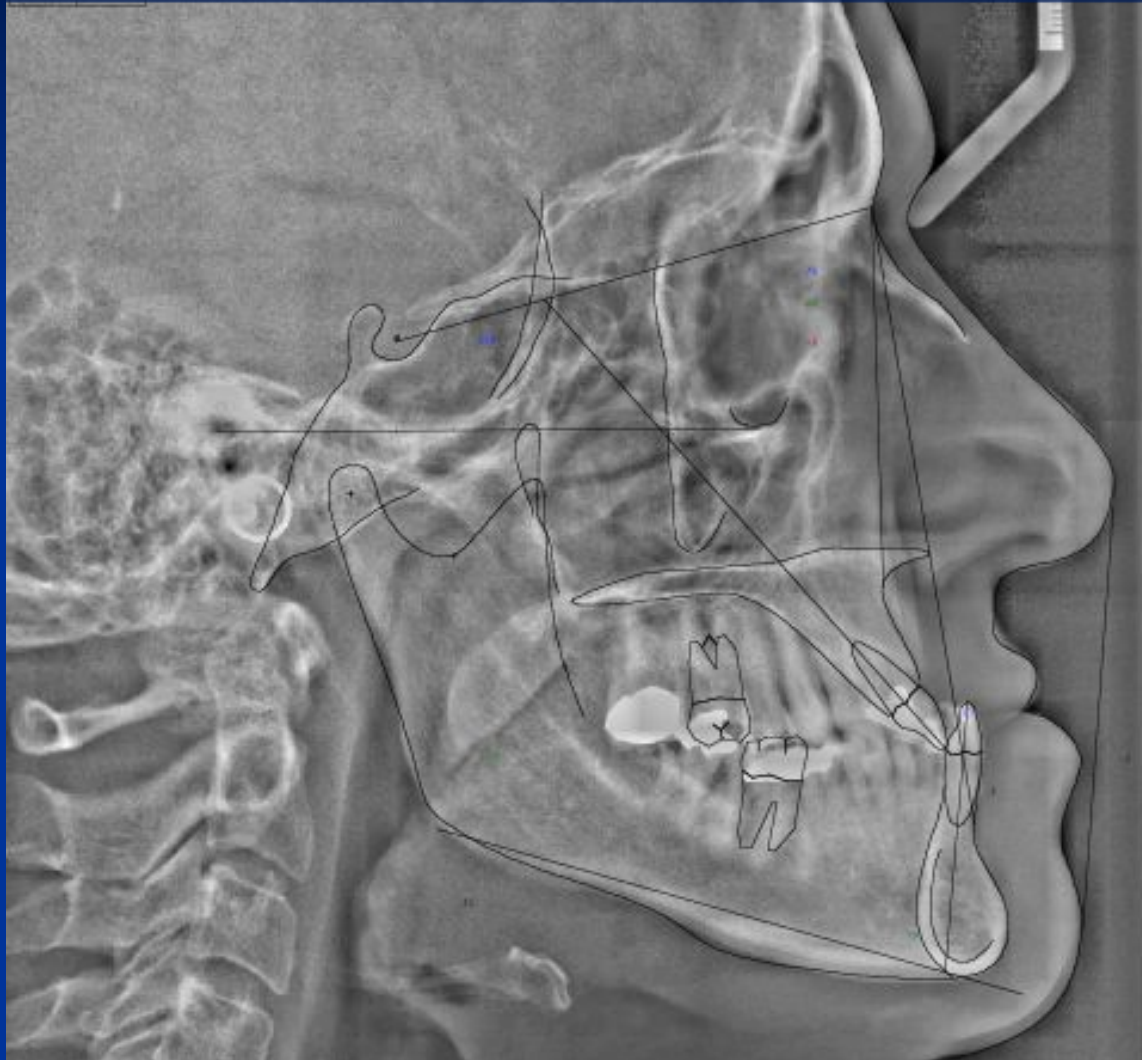Dental Crossbite



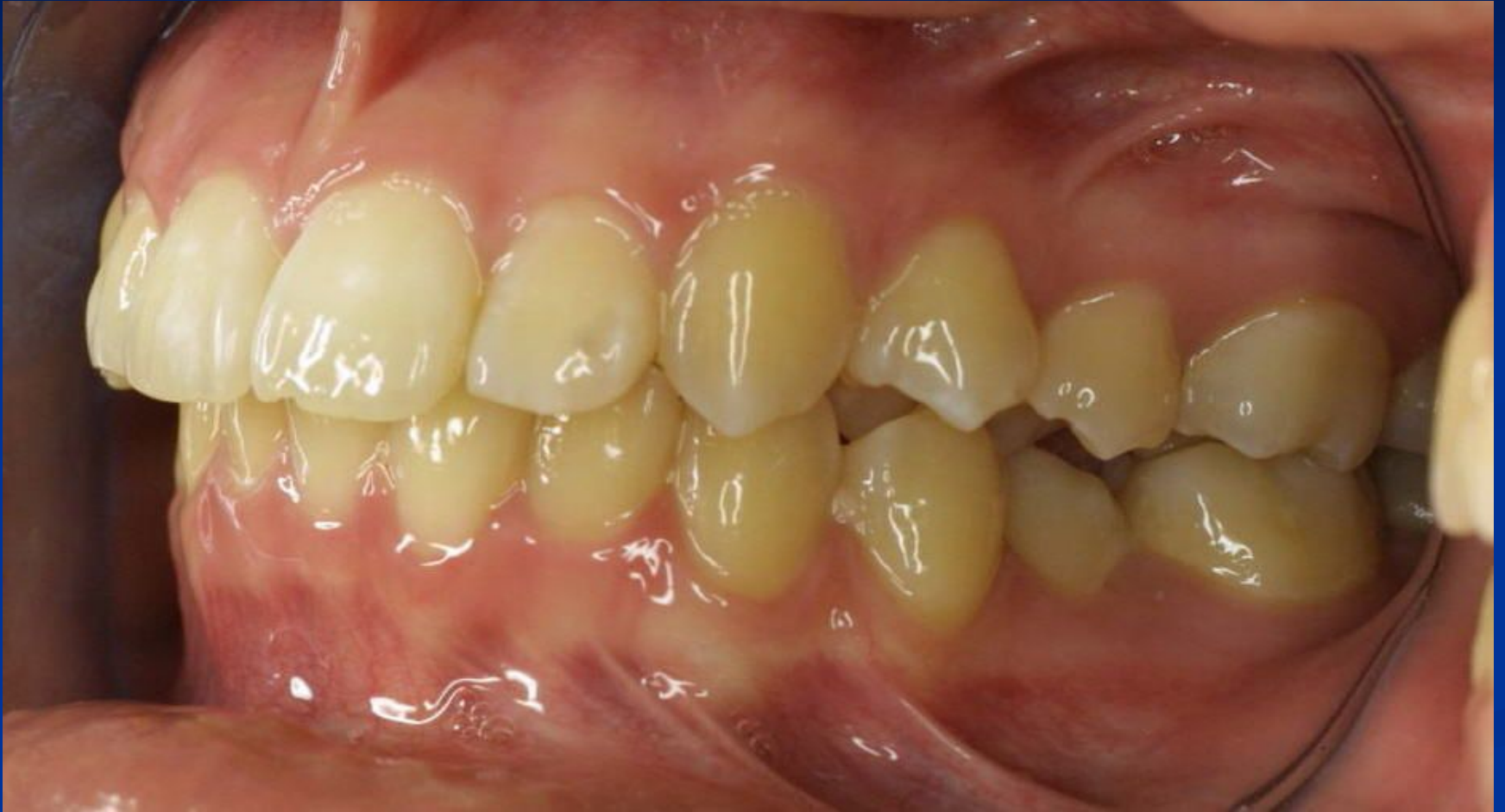Anterior



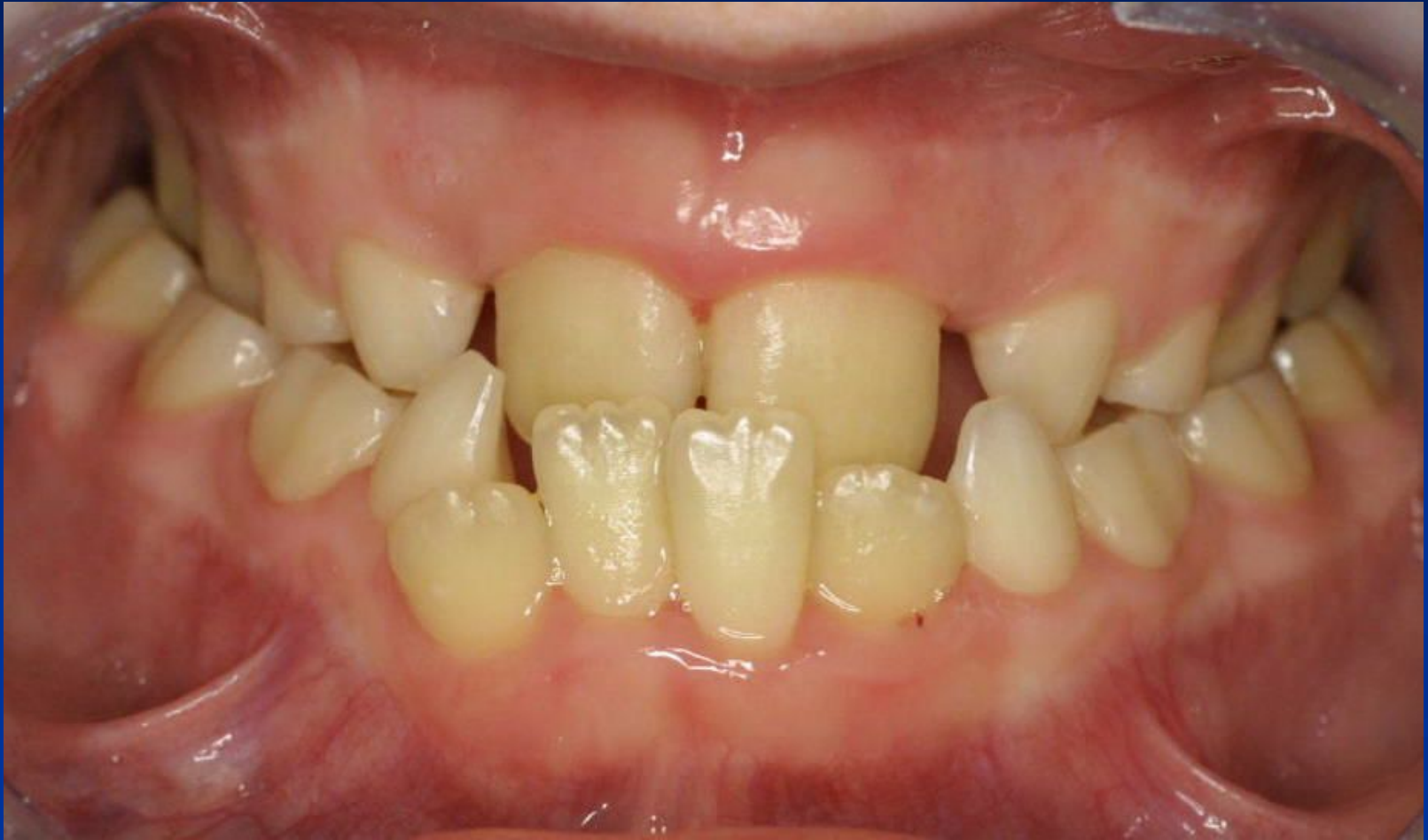Skeletal Crossbite



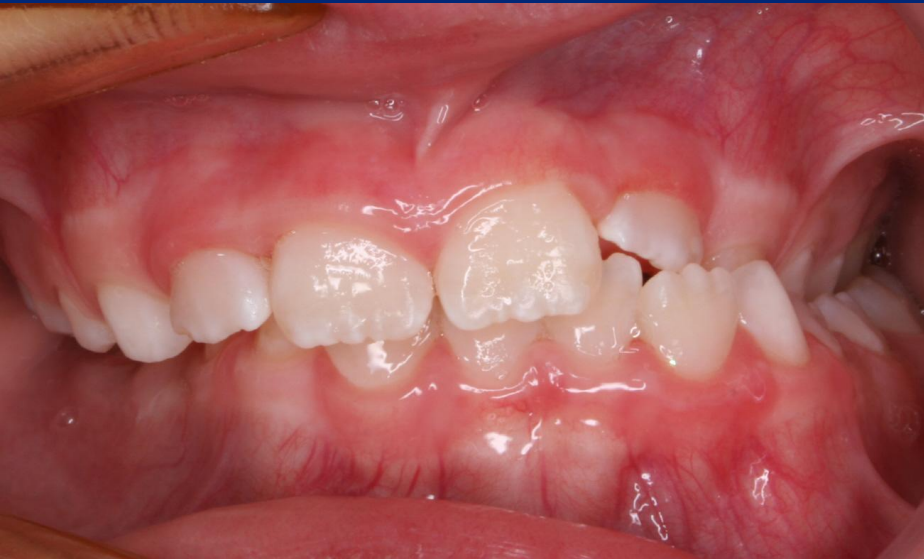Dental Crossbite (posterior)



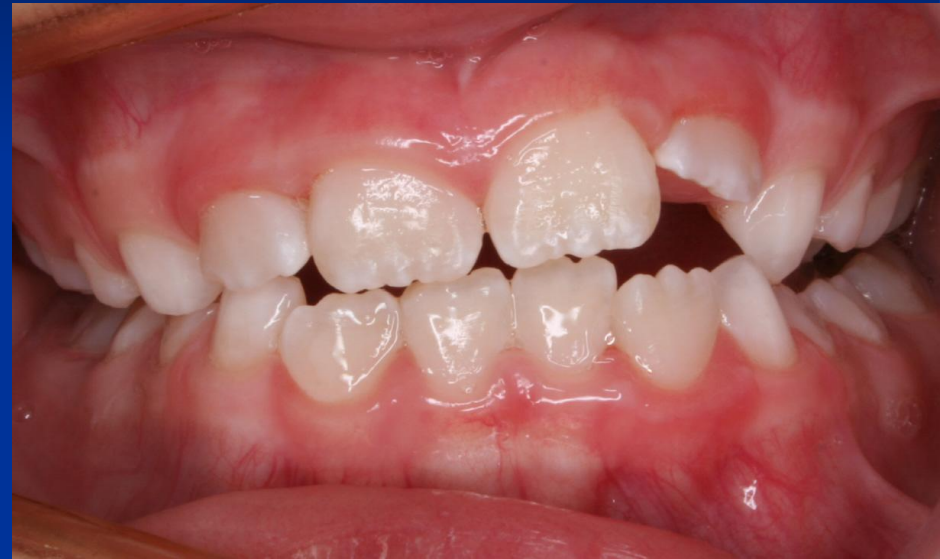Bilateral Post and Ant Crossbite



Functional Shifts

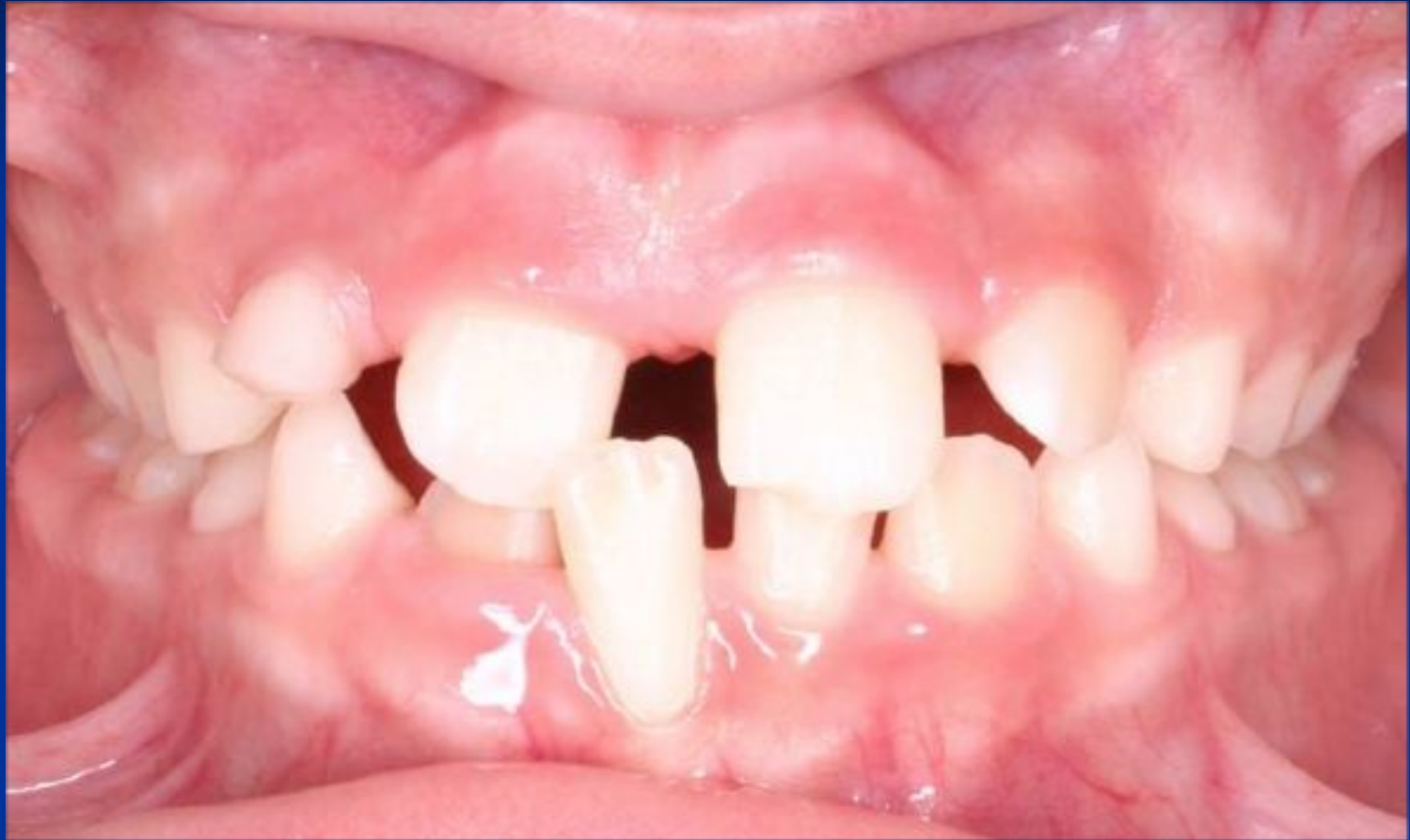

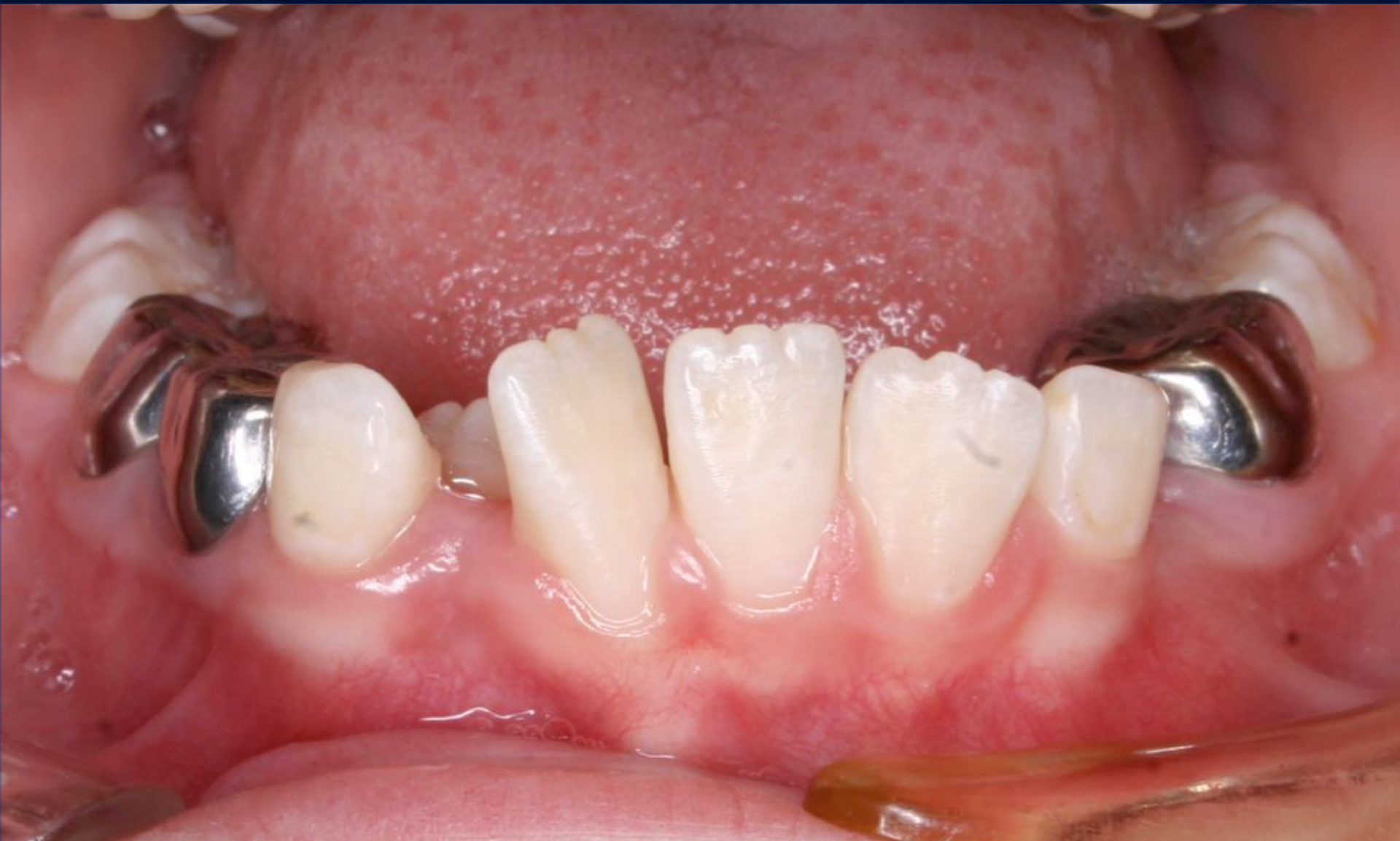CO



CR

Soft Tissue Considerations



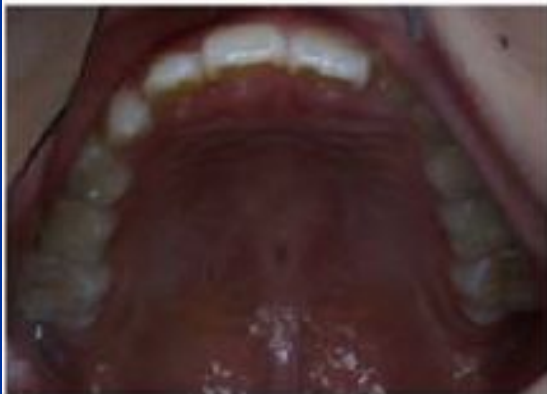
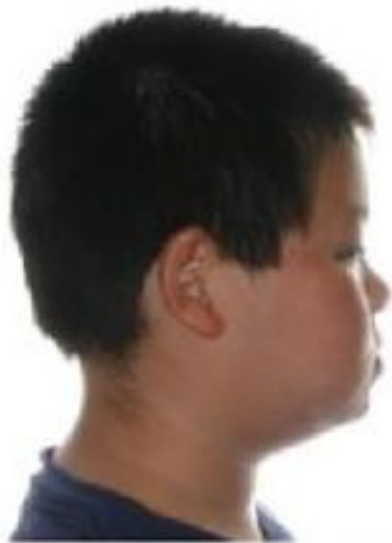
Timing of Treatment of Class III Malocclusion

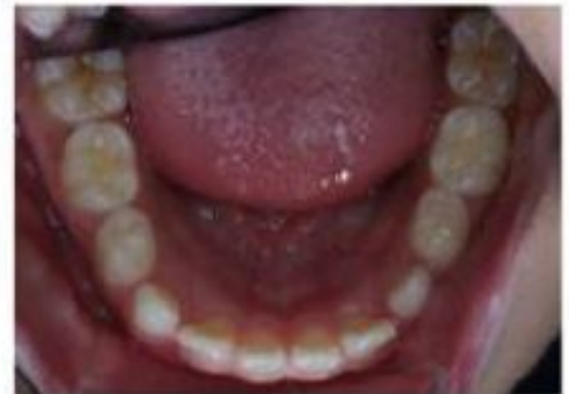- Patients exhibiting characteristics of a Class III malocclusion, especially those with an anterior crossbite should be treated earlier
 - Best to start when the upper laterals are erupting if the skeletal discrepancy is minimal to moderate
- Younger patient are more cooperative
- Severe class III cases are best treated near the end of growth

Timing of Treatment of Class III Malocclusion

- Eliminating anterior crossbite early may prevent a skeletal problem
- The prognosis for orthopedic intervention (protraction and expansion) worsens as patient develops beyond puberty
- Unless psychological trauma is imminent, delay severe class III corrections until all skeletal growth completed

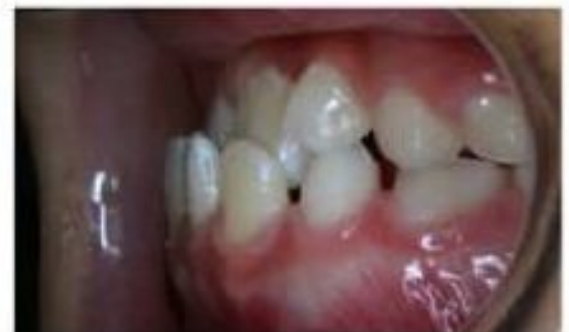
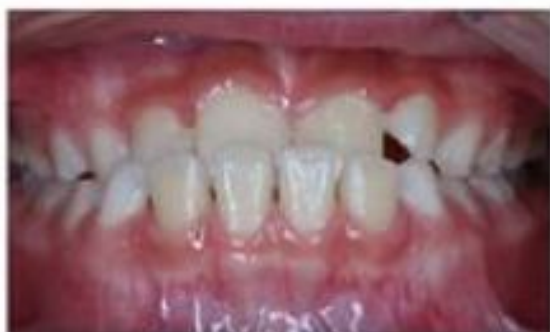
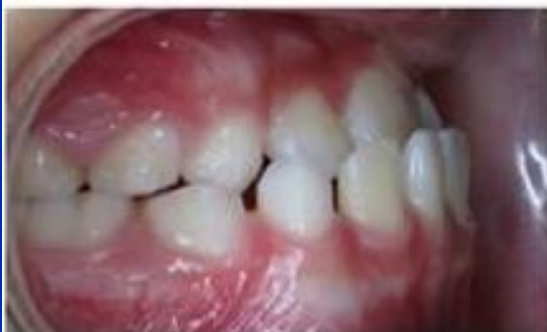Joseph Yuen
Patient Chart #037094
Initial
Date Image Taken 7/15/2009
Patient Birthdate 9/25/1998

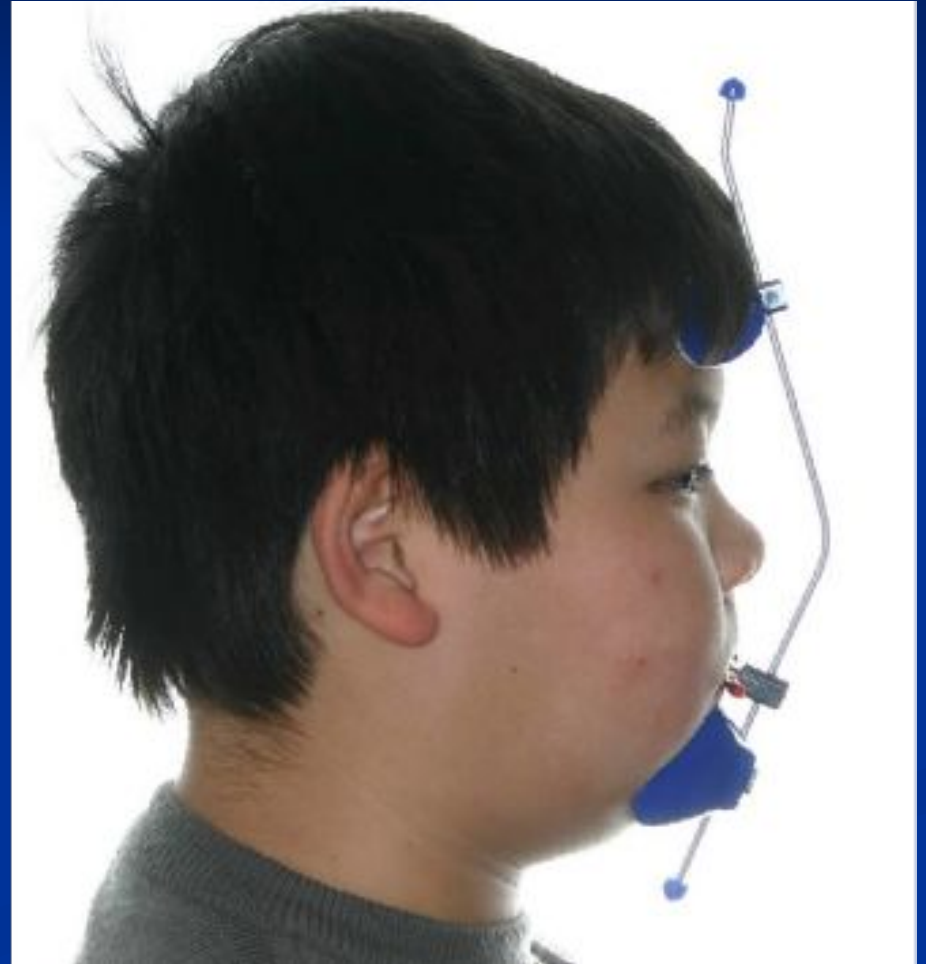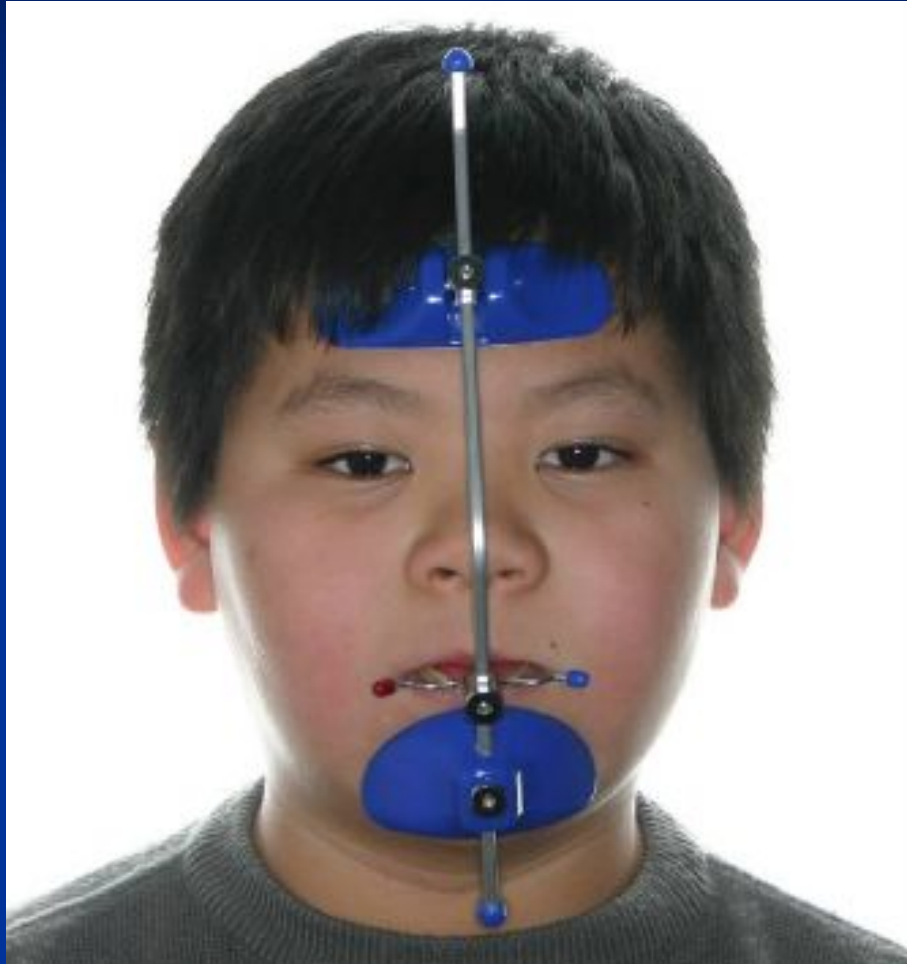


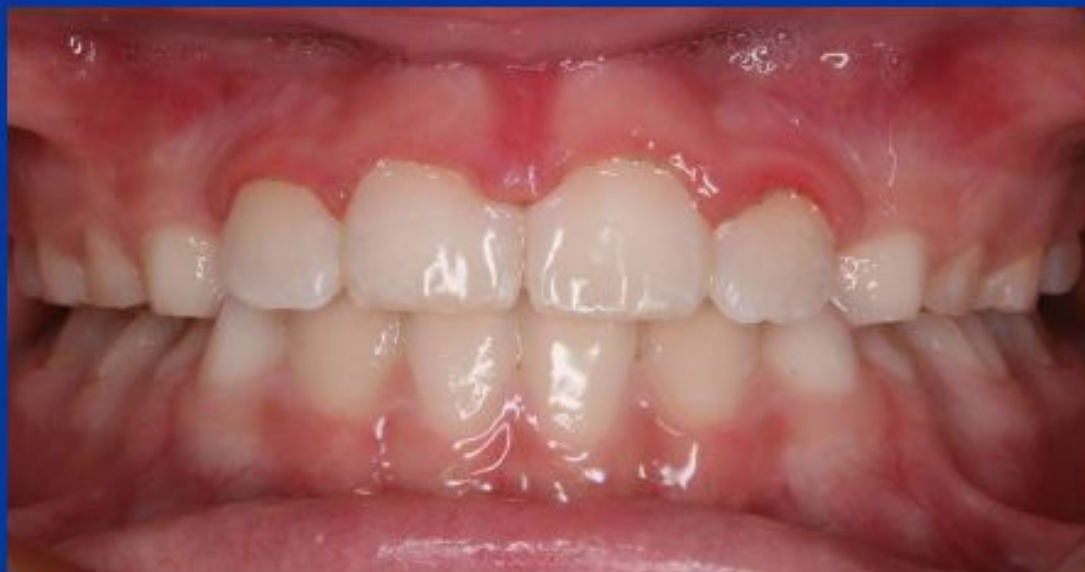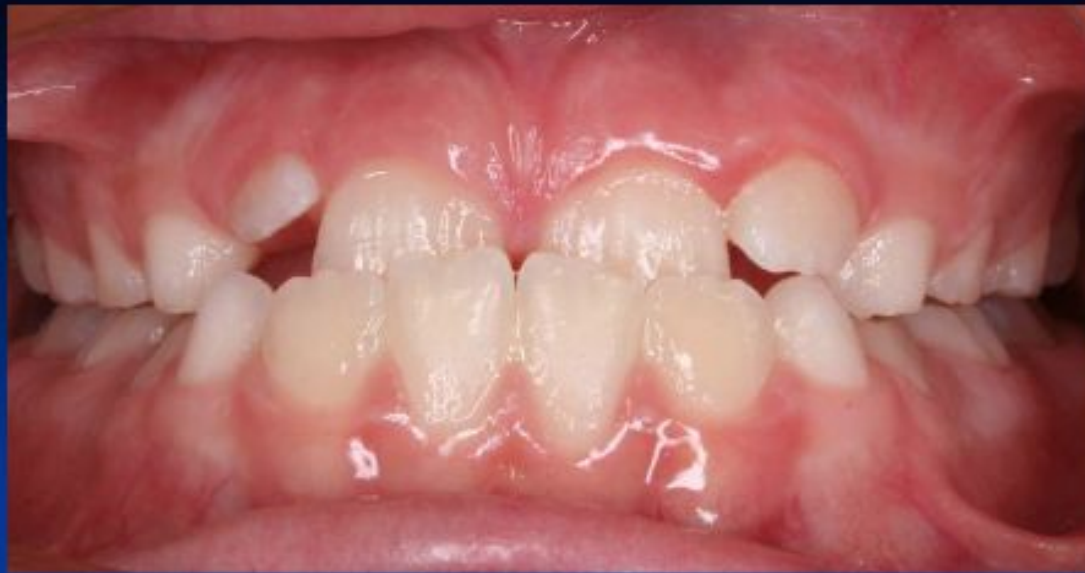Stanton Henry DDS, MDS

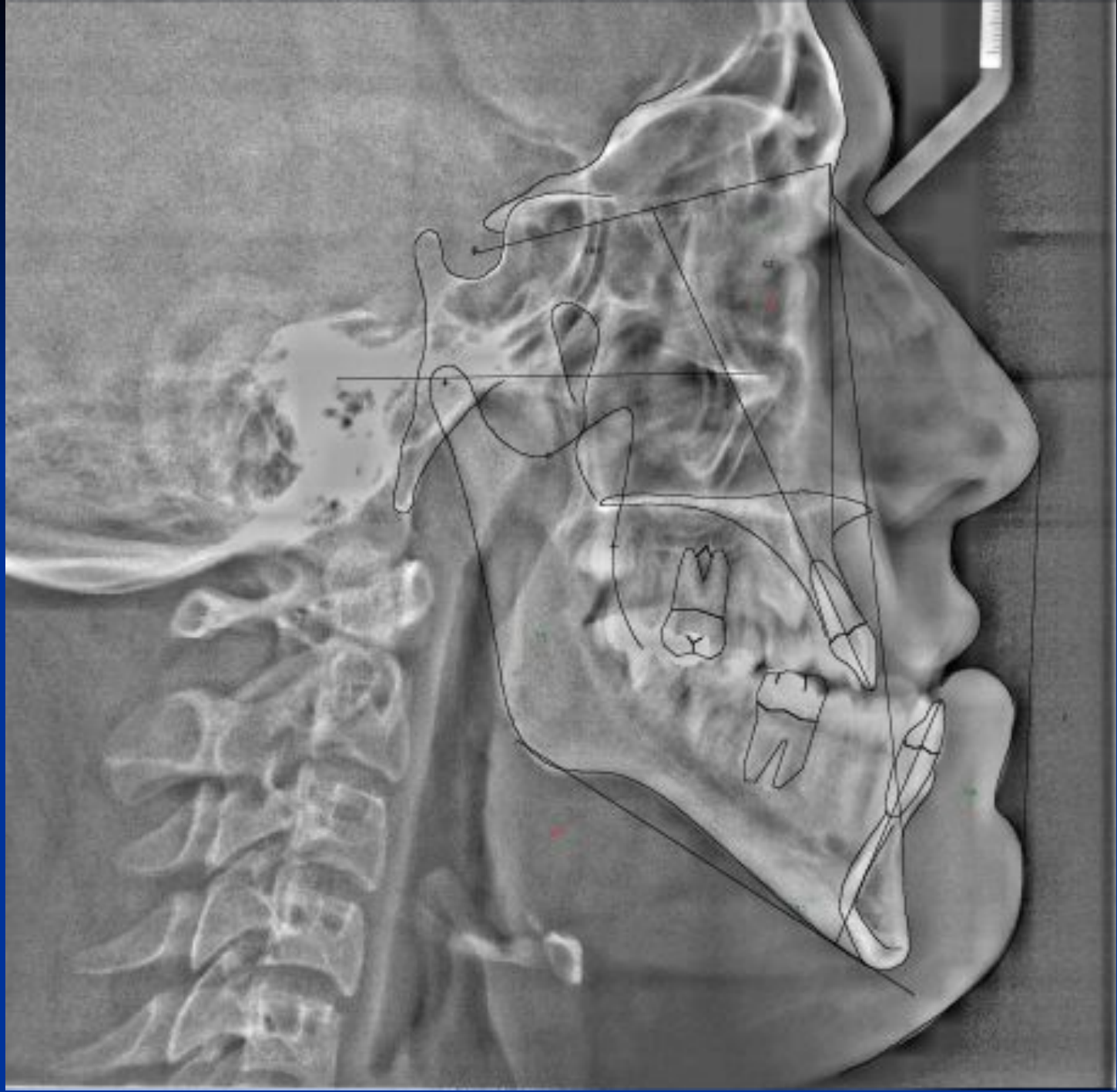Dustin Roden-Johnson DDS, MS



Face Mask



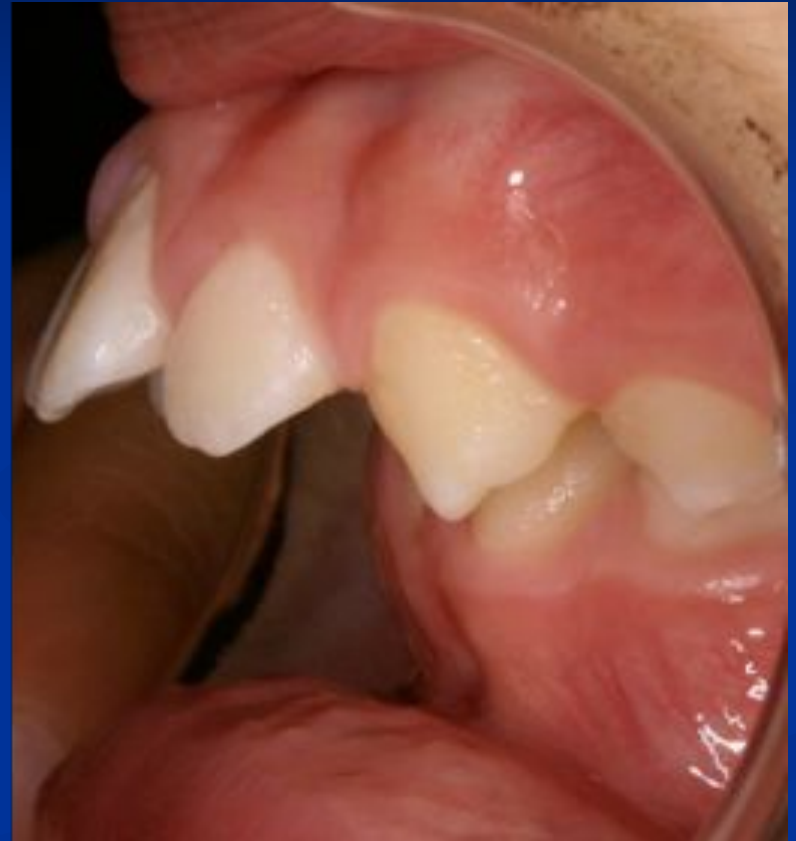
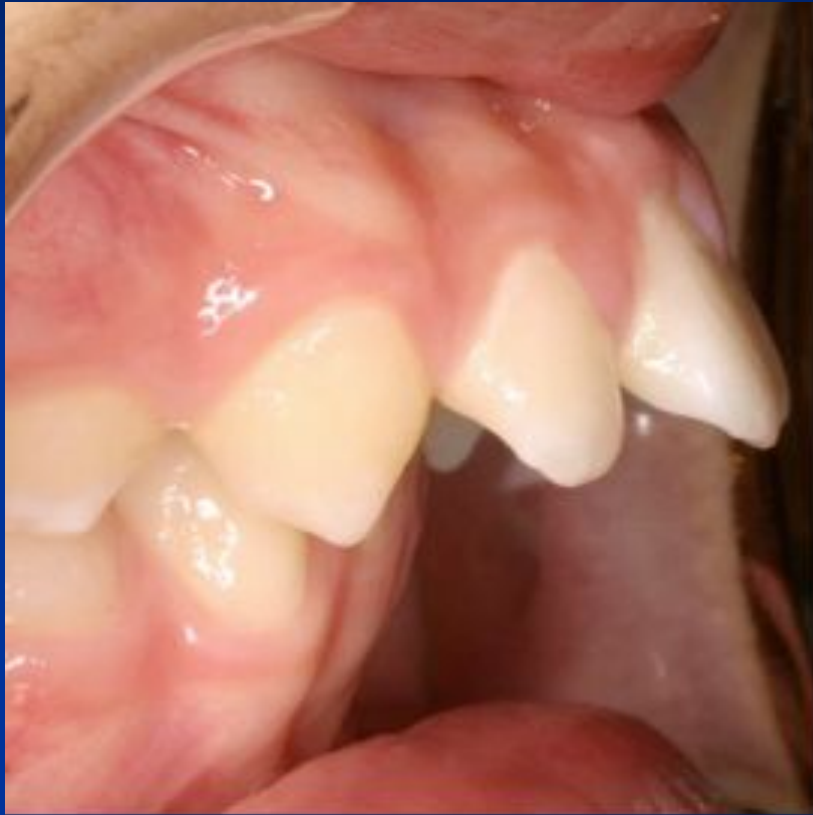


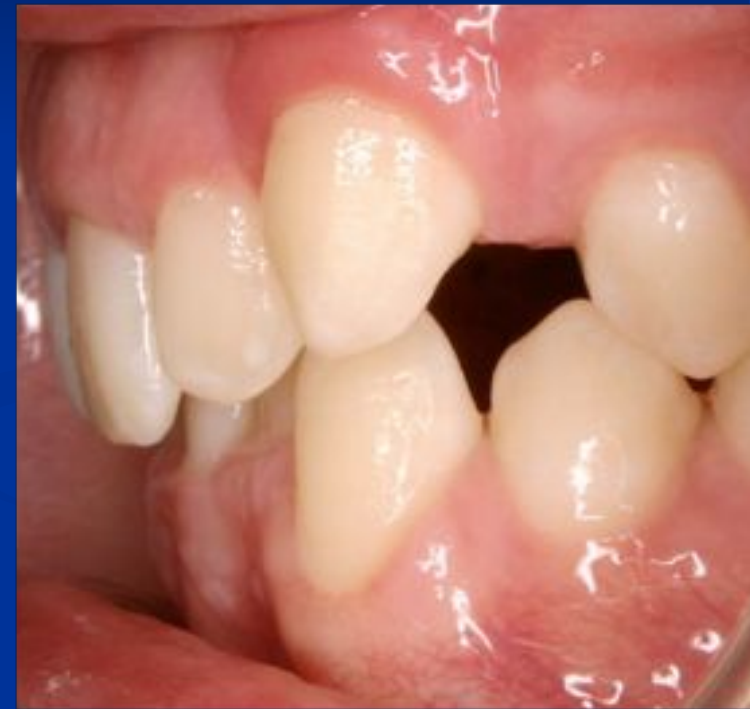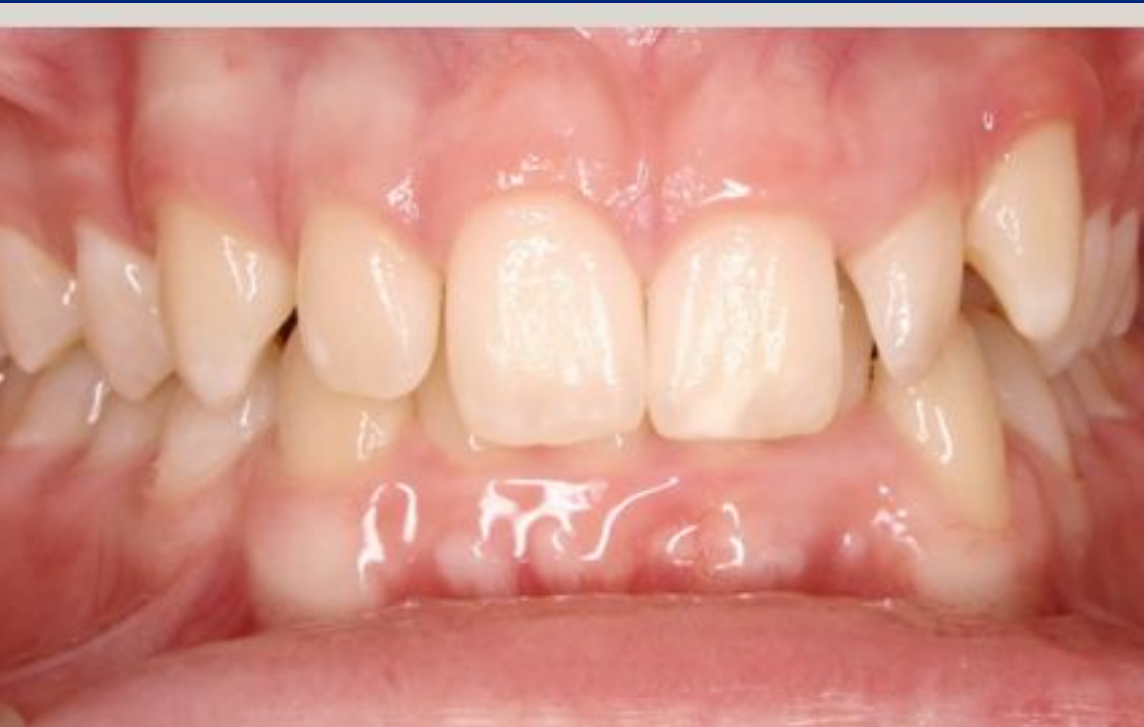Class II

- Like class III the timing of tx can depend on the situation
- It is often best to tx the class II pt when they are entering puberty and have most of the permanent dentition
- Some class II malocclusions are best to address early and in 2 phases of tx

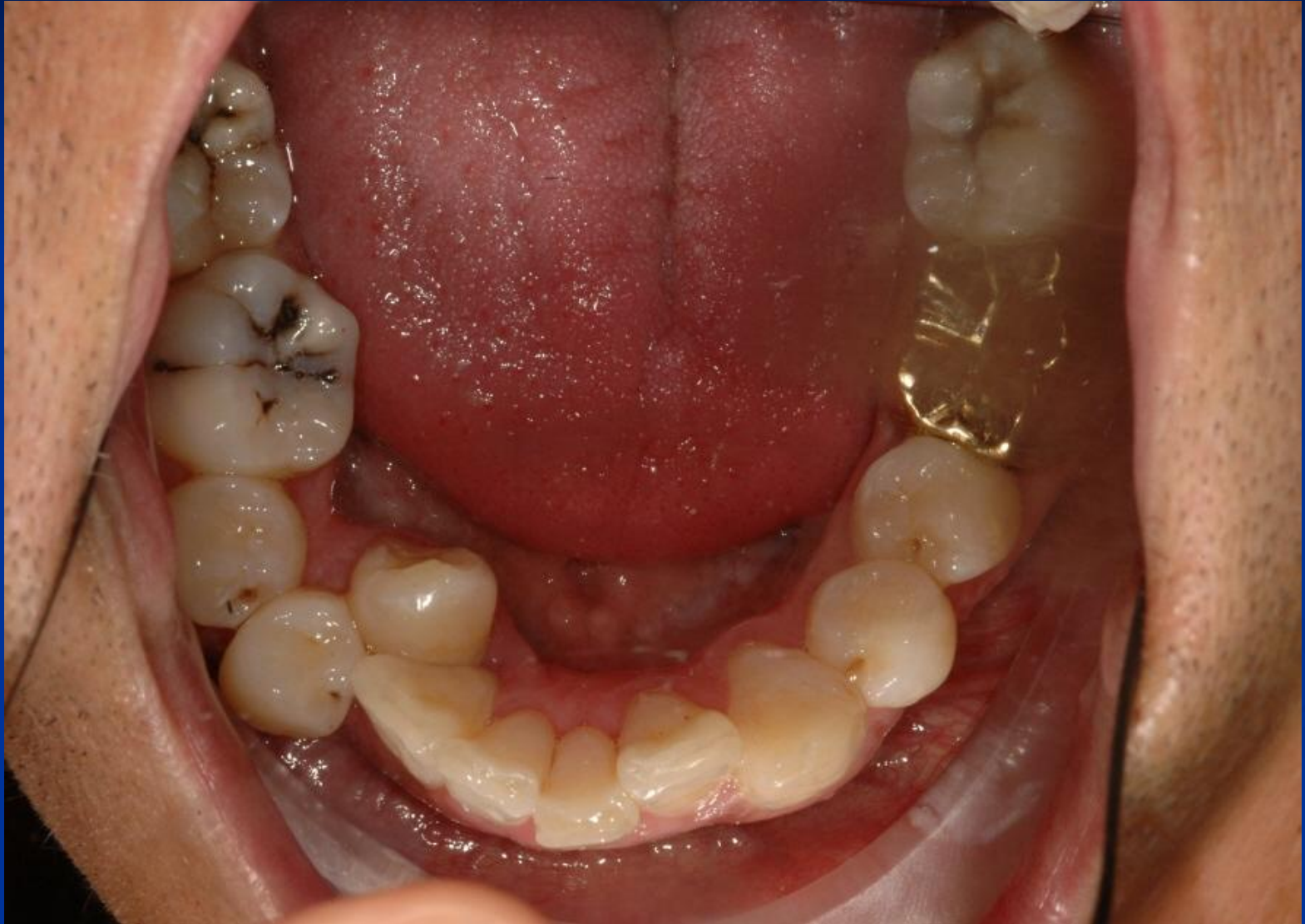
Excessive Overjet



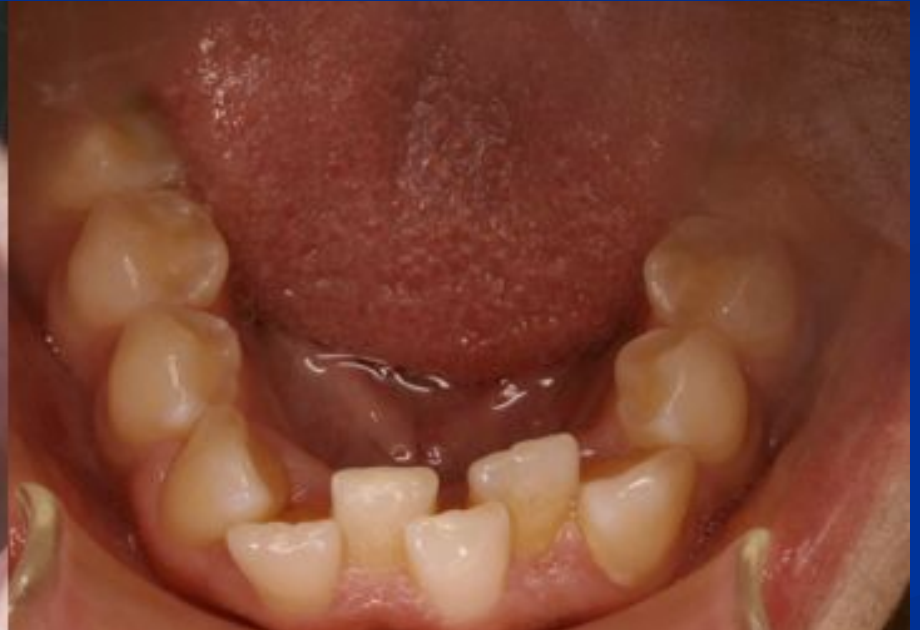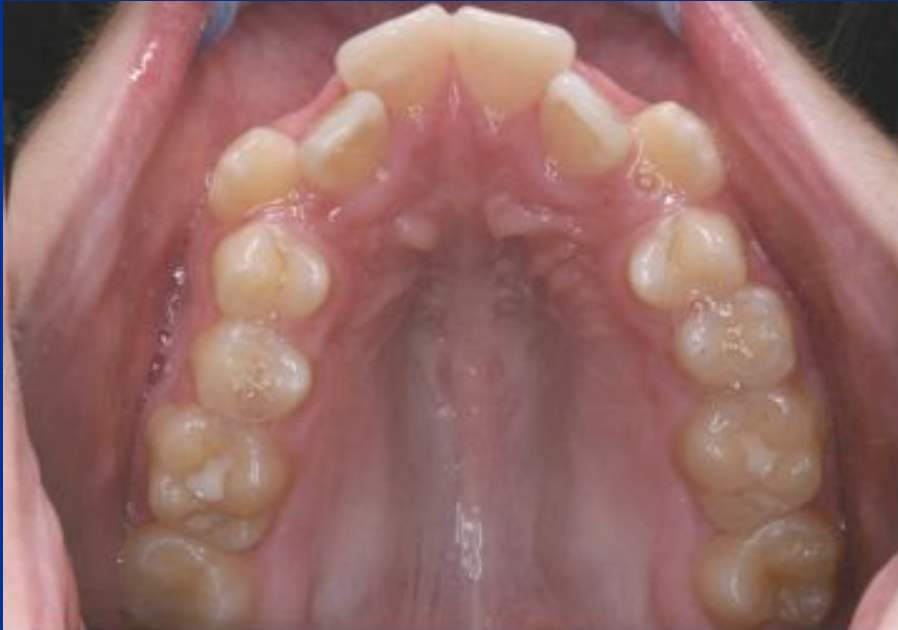Excessive Overbite



Crowding



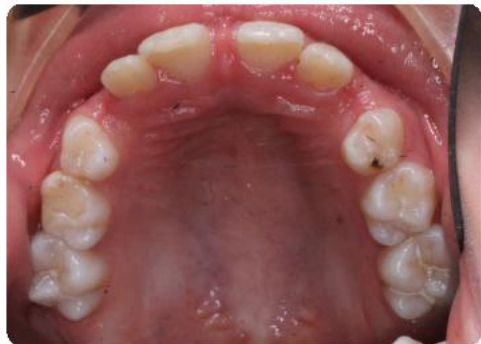Crowding



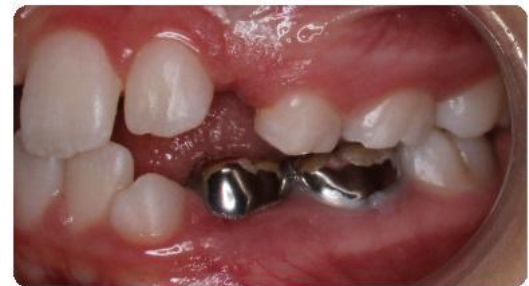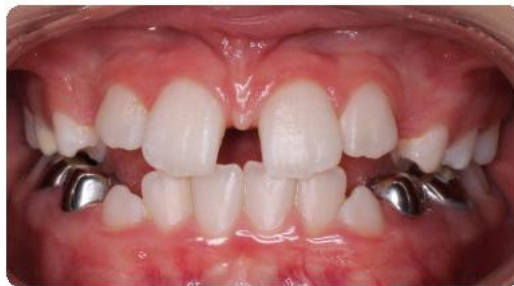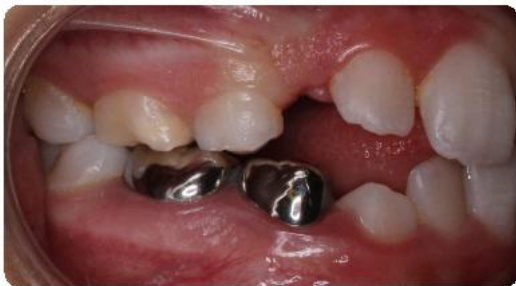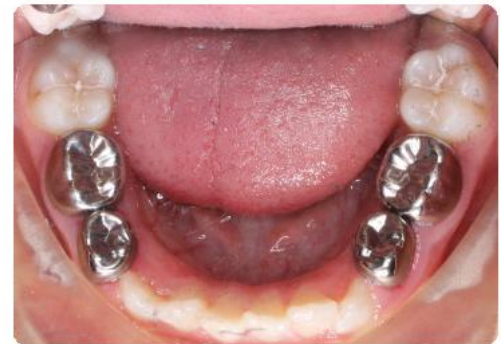Esthetics

- Often a tough subject to engage with parents
- Many families want to have better esthetics for their children but need an invitation
- Kids and be brutal and teeth are often the subject





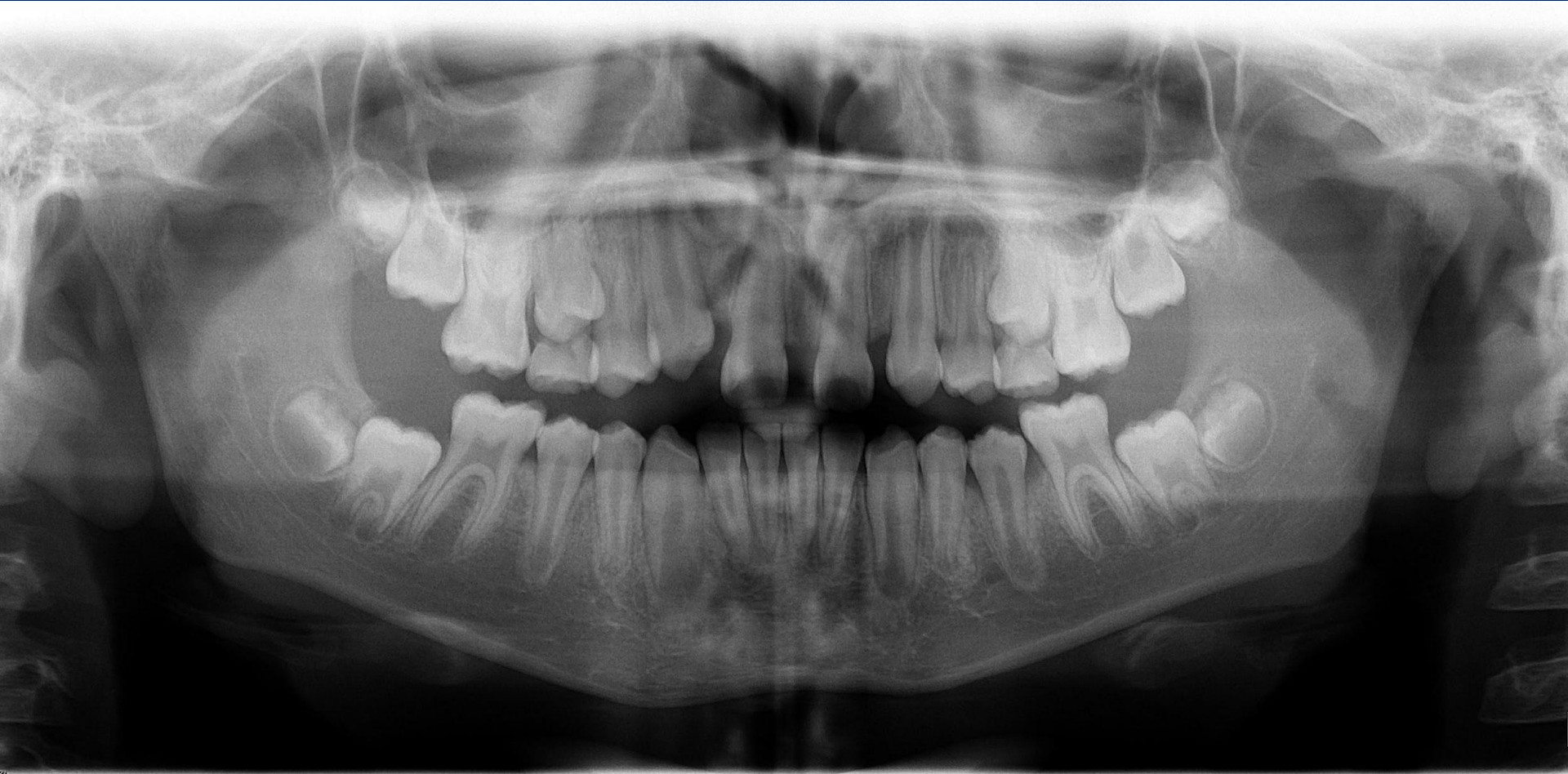Lillian Wagenknecht
D.O.B. 10/30/2007 10
Yrs. D.O.S. 4/5/2018

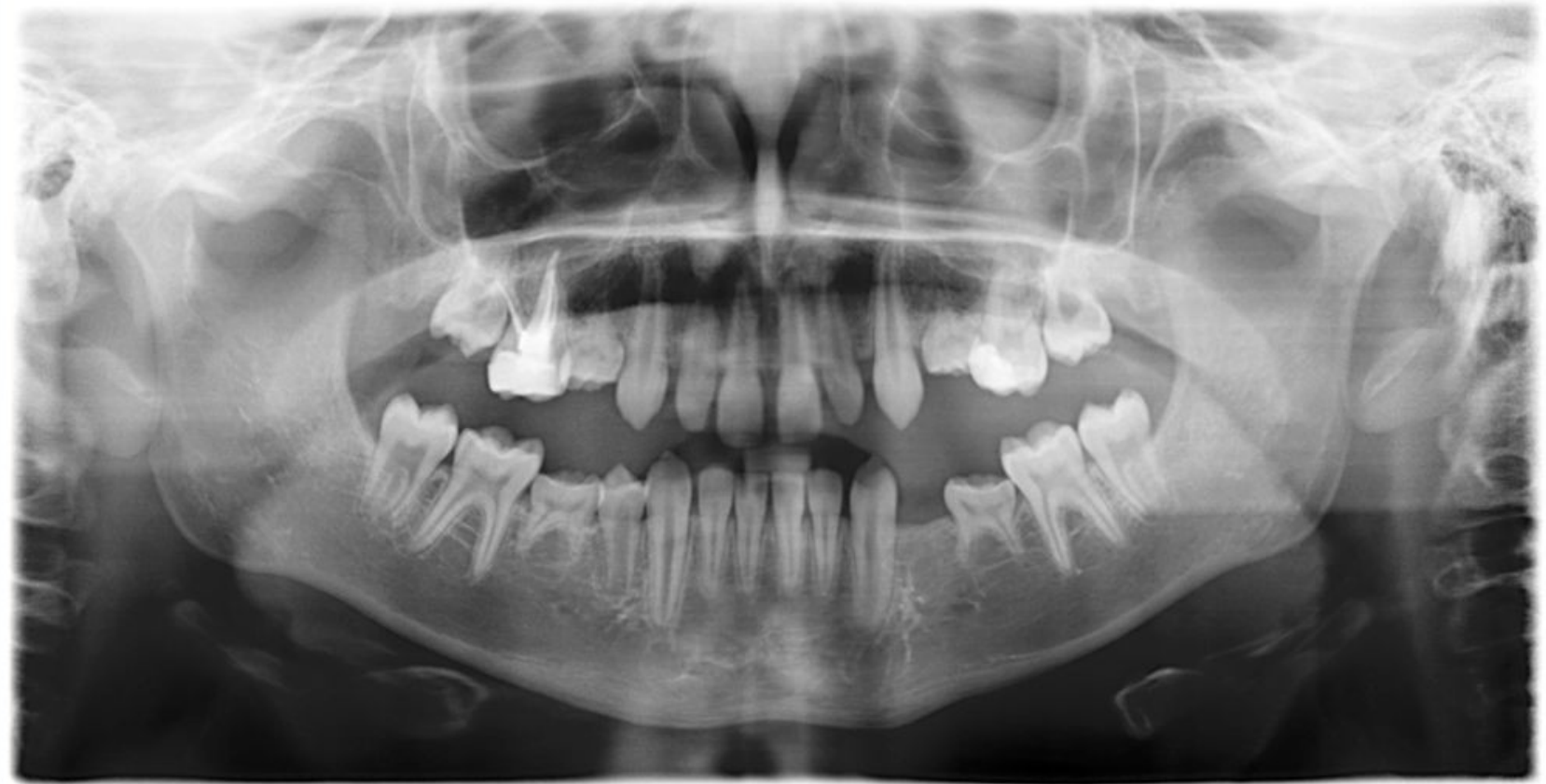

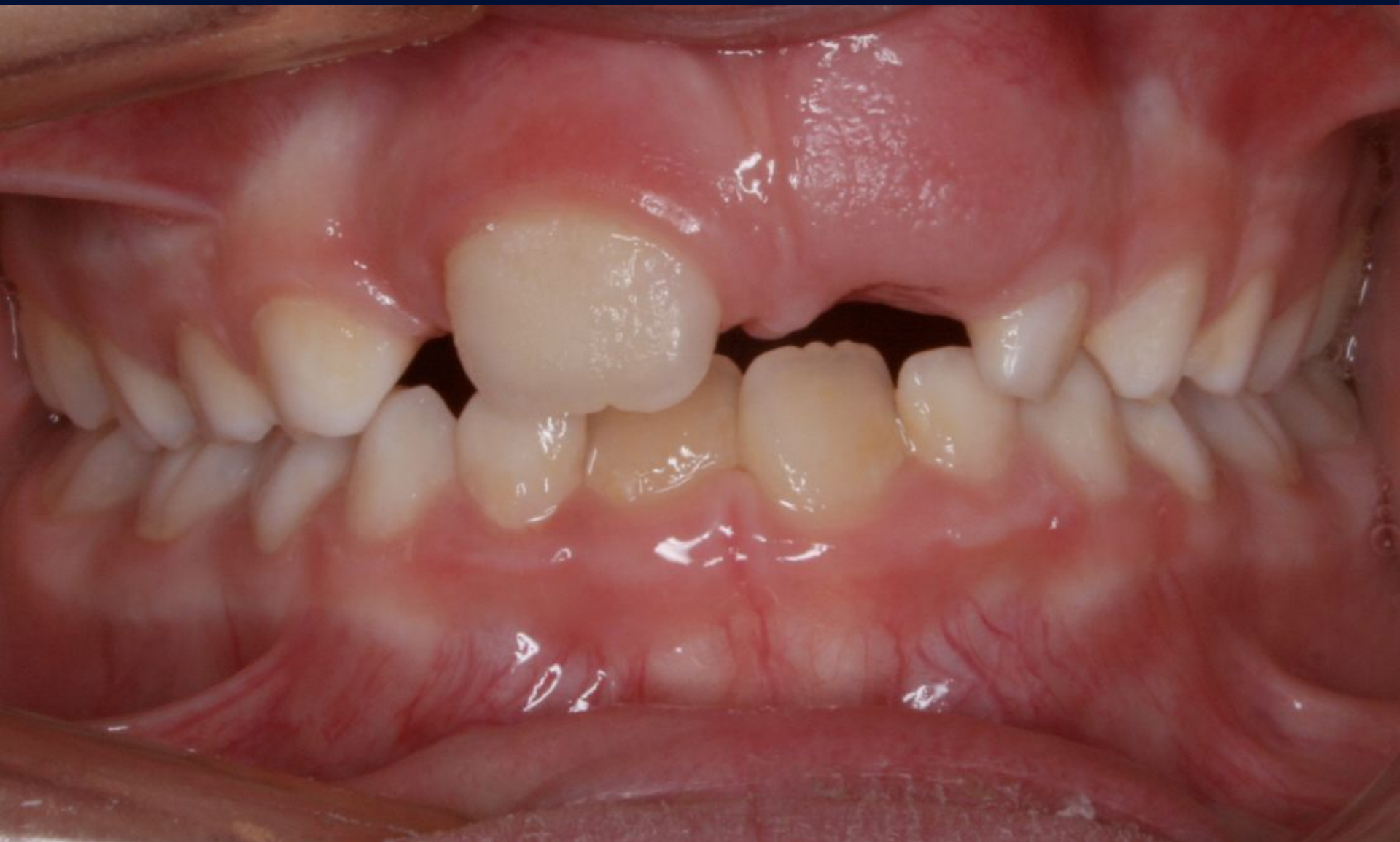Timing of Panos

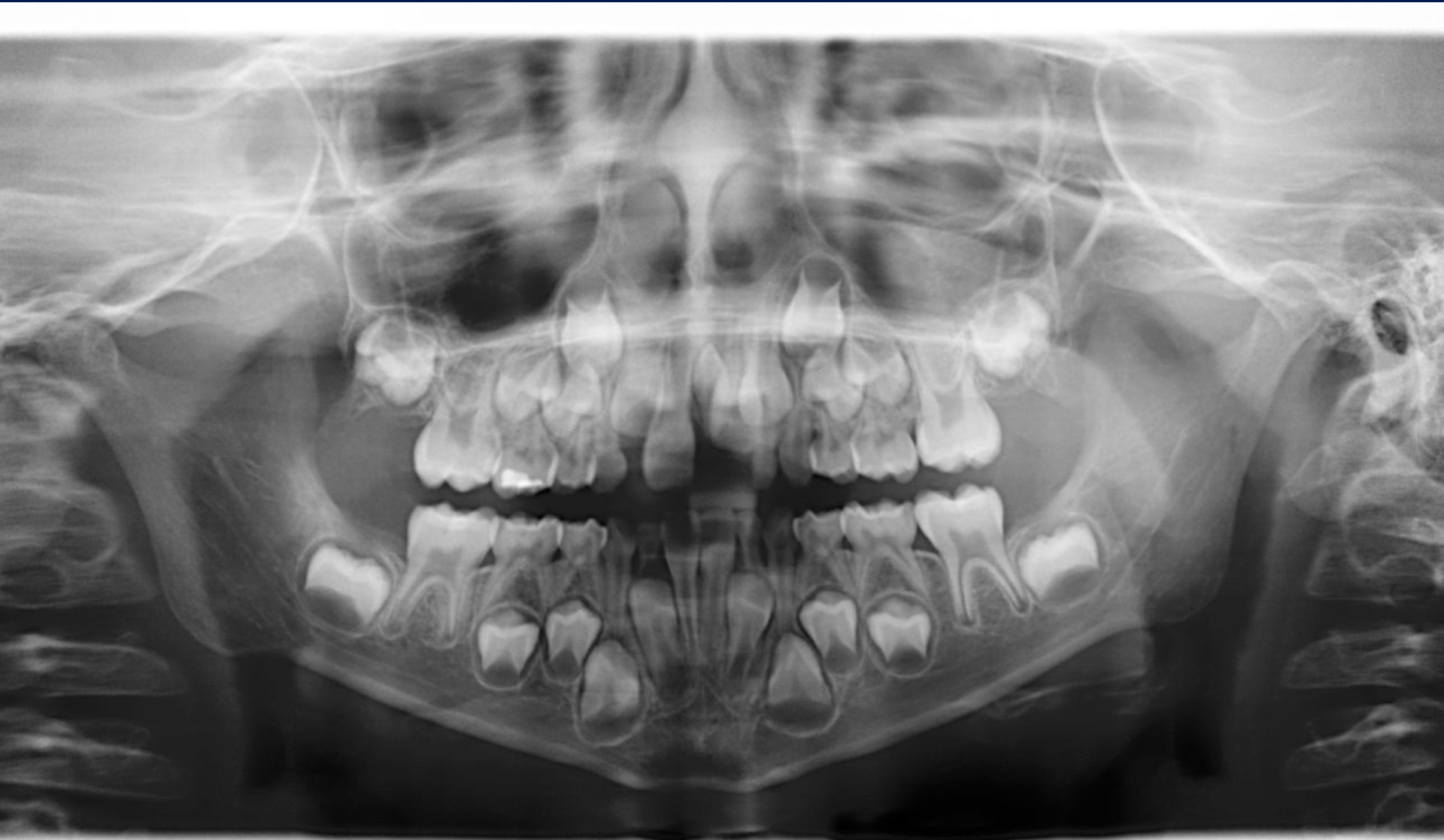- Panos should be taken at the latest when the 1st molars have erupted
- This is usually around the age of 6 or 7
- Counting teeth
 - Missing teeth
 - SN teeth
- Identifying ectopic teeth
- Eruption order

Counting Teeth

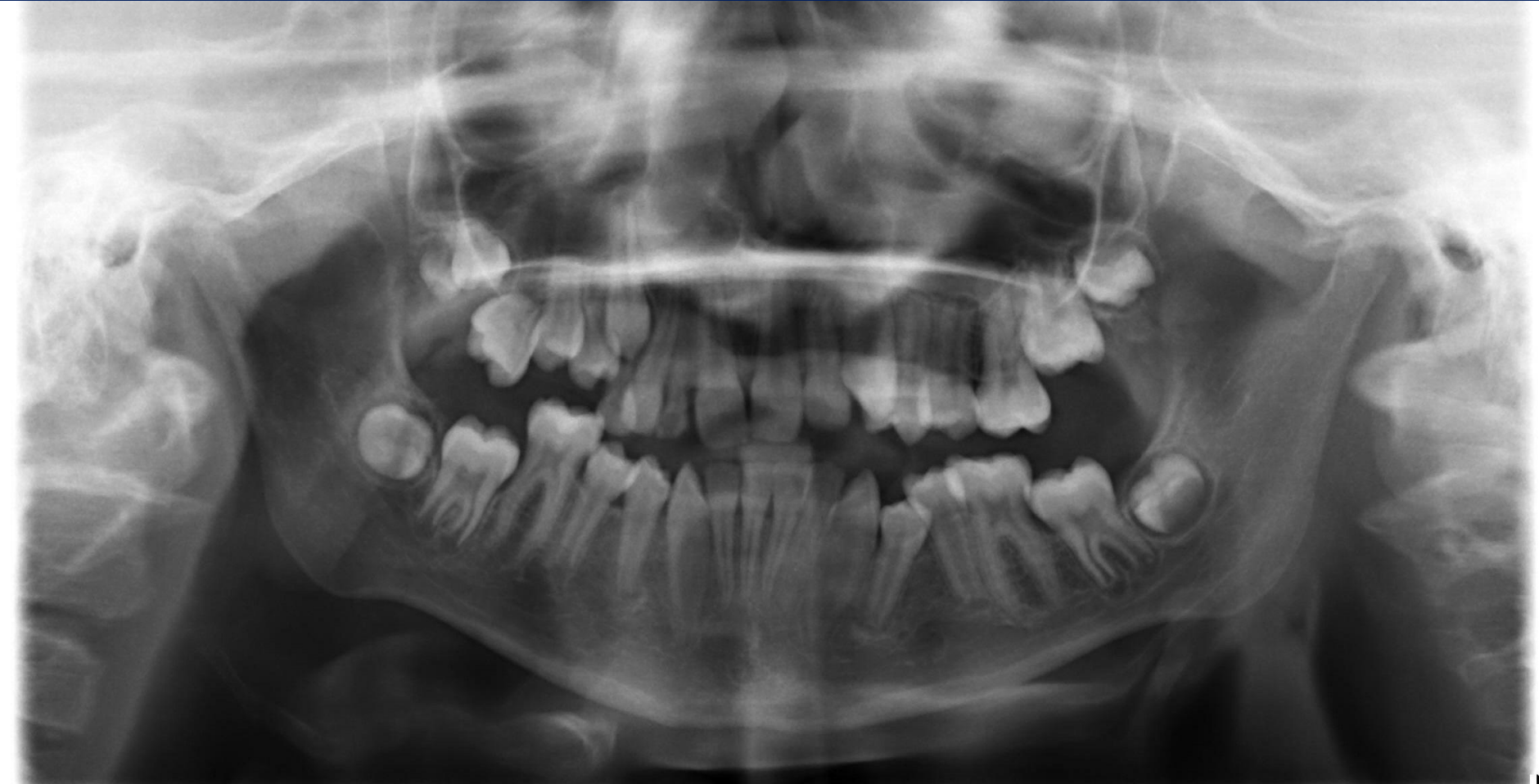




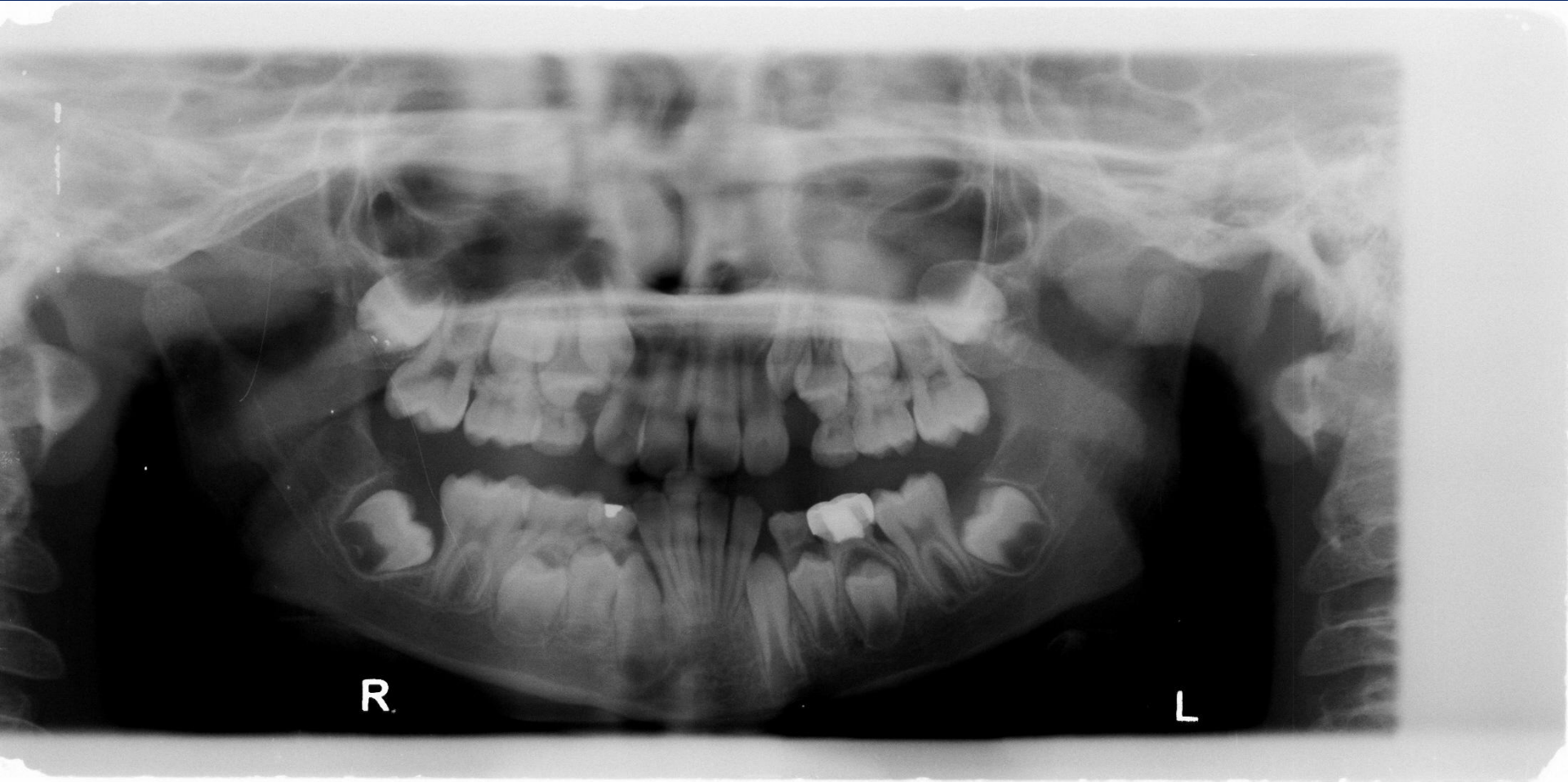


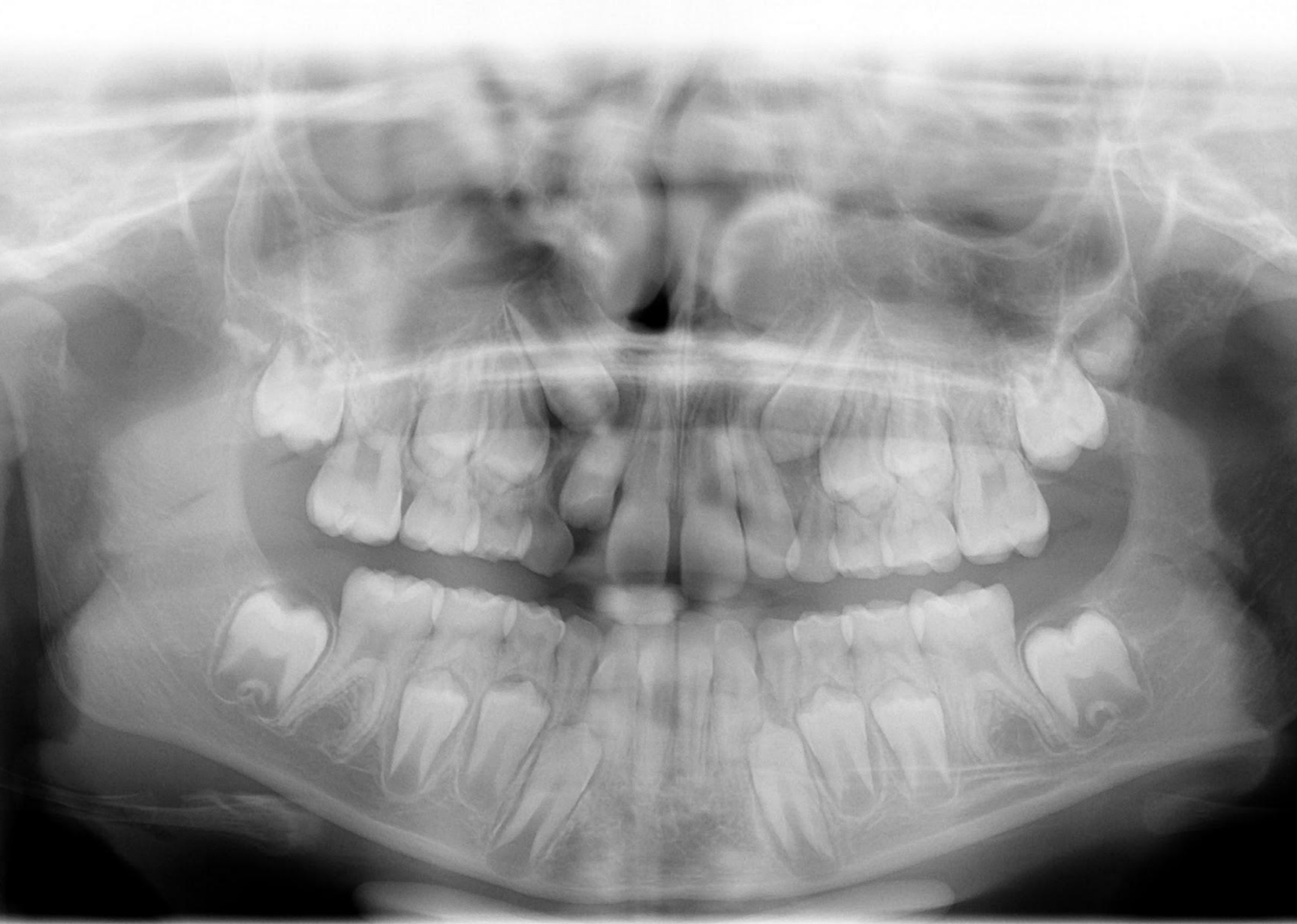Eruption Order and Retained Primaries

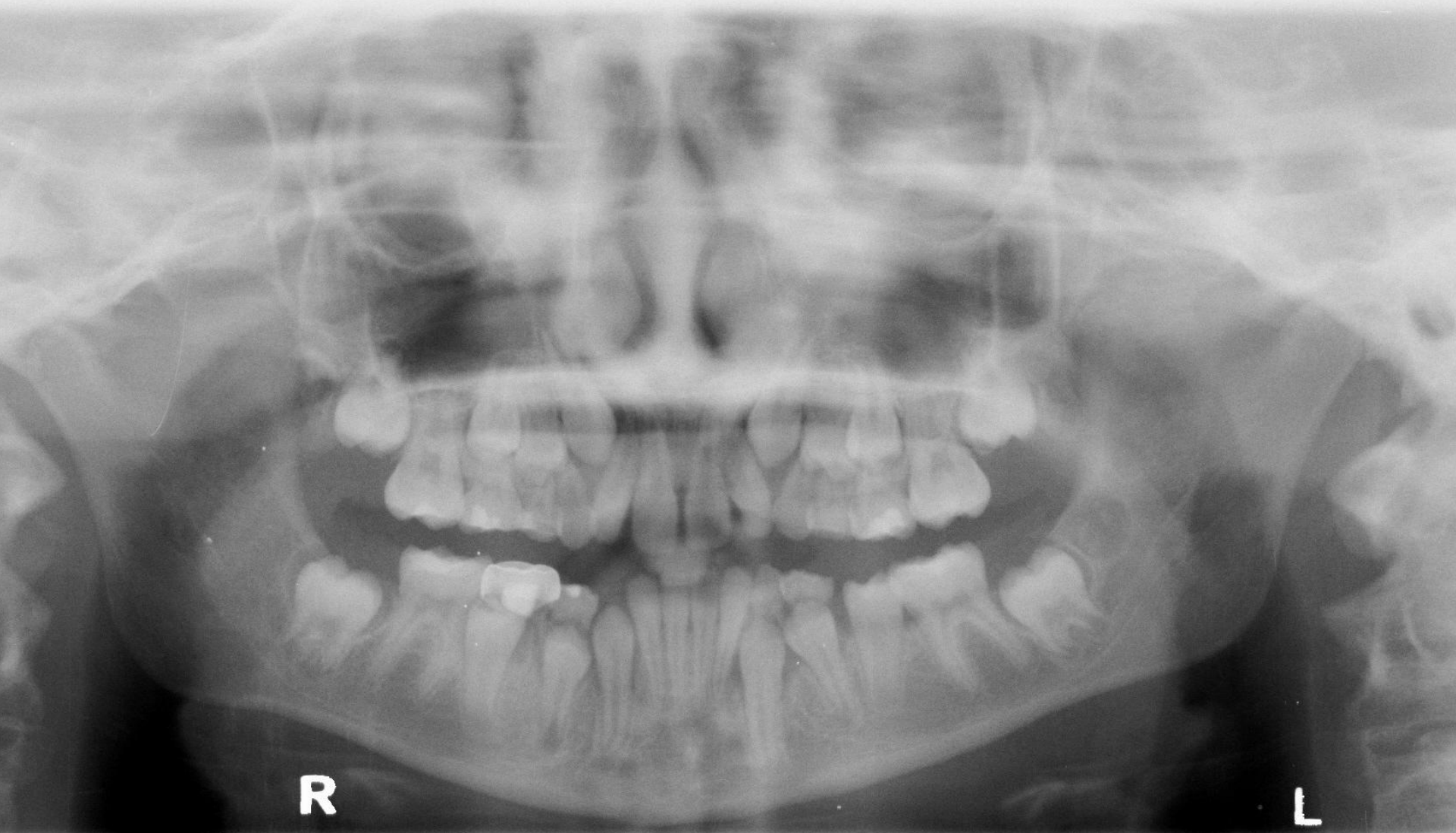


Severe Crowding



Development of Canines





R

L